

Piroon Mootsikapun, M.D.

A 56-year-old man presented with a low-grade fever and productive cough with foul-smell sputum, 1 month prior to admission. He also had weight loss of 3 kilogram. Physical examination revealed decreased

breath sound and egophony sound at his right lung. Chest roentgenogram showed a large cavity at his right lung (Figure 1). Sputum Gram stain is shown in Figure 2.

What are your diagnosis and appropriate management?

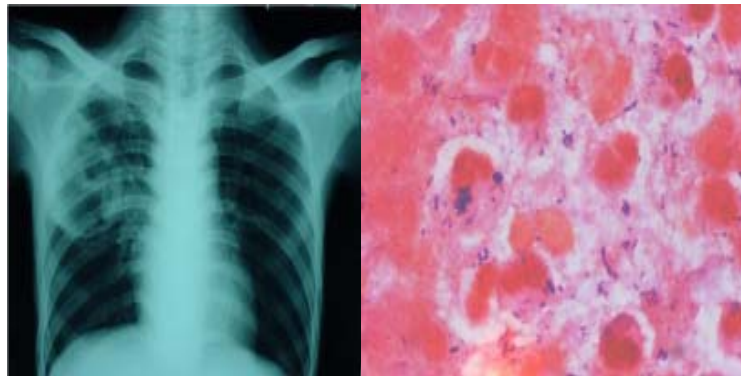


Figure 1.

Figure 2.

(Please see the answer of this Photo Quiz on page 105)