

Piroon Mootsikapun, M.D.

A 46-year-old diabetic man presented with a low-grade fever and right-upper-quadrant abdominal pain for 10 days. Physical examination was normal except mild hepatomegaly with tenderness. Abdominal ultrasonogram showed a single large hypoechoic

lesion of the right lobe of liver, compatible with a liver abscess. Cefotaxime was intravenously given, and the abscess aspiration was performed. Gram stain of the pus revealed organisms as shown in Figure 1.

What is the diagnosis and management?

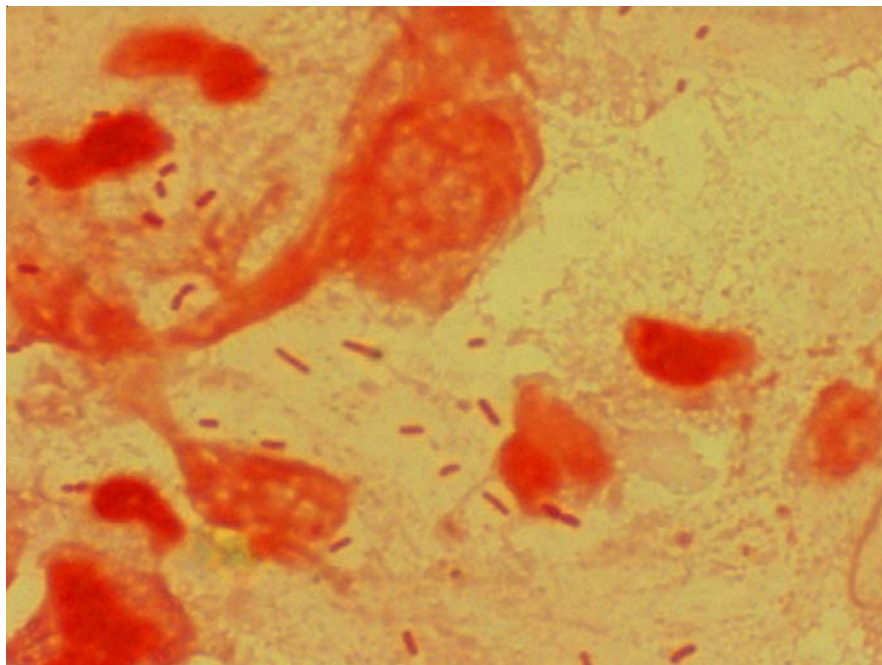


Figure 1.

(Please see the answer of this Photo Quiz on page 165)