

A 46-year-old Cirrhotic Man Presented with High Fever, Chills, Confusion, and Right Leg Swelling and Tenderness for 1 Day

Piroon Mootsikapun, M.D.

A 46-year-old cirrhotic man presented with high fever, chills, confusion, and right leg swelling and tenderness for 1 day. He went to seashore and ate many seafood meals, 2 days previously. Physical examination revealed temperature of 39°C, a blood pressure of 90/

60 mmHg, respiratory rate of 24/minute, heart rate of 100/minute, jaundice, and erythematous purplish rash with hemorrhagic blebs on his right leg. He also had a swelling right knee joint. Gram's stain of the fluid from the joint fluid and bleb revealed organisms as shown in Figure.

What is your diagnosis and management?

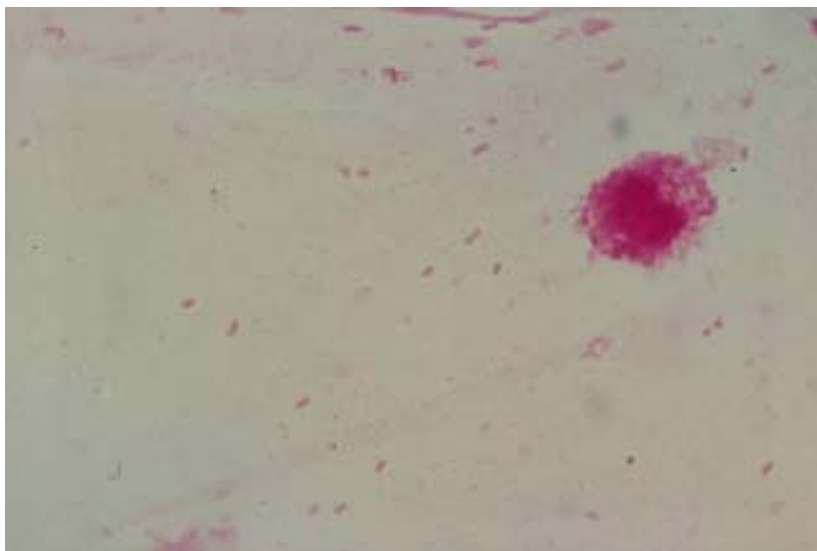


Figure.

(Please see the answer of this Photo Quiz on page 133)