

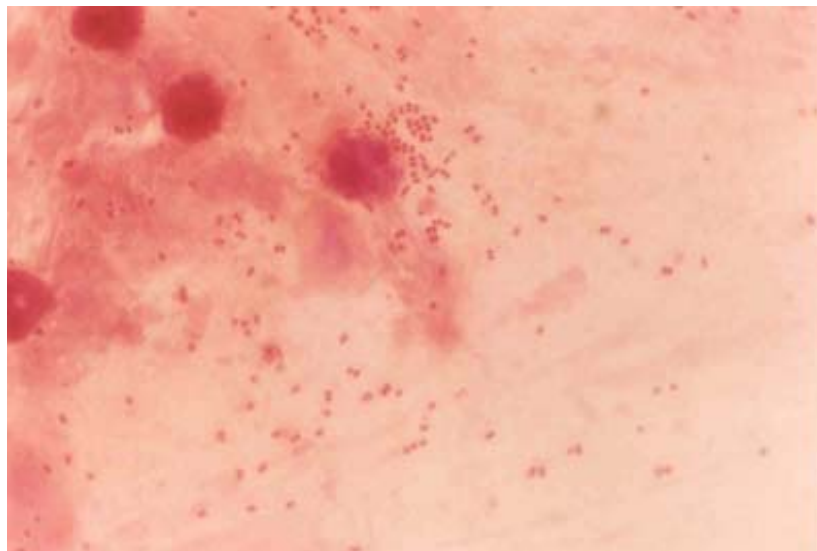
# A 62-year-old Man Admitted in a University Hospital for a Week with Subdural Hematoma

**Piroon Mootsikapun, M.D.**

A 62-year-old man admitted in a university hospital a week ago because of subdural hematoma. He was intubated and on mechanical ventilator since then. He developed spikes of fever and respiratory distress last night. Physical examination revealed T

39.5°C, BP 110/60 mmHg, RR 34/min, HR 120/min and crepitation at right lower lung. Chest radiograph showed alveolar infiltrates right lower lung. Tracheal aspirate was obtained and its Gram stain revealed as shown.

What is your diagnosis and management?



**Figure.**

(Please see the answer of this Photo Quiz on page 53)