

A 34-year-old Man Presented with Low-graded Fever and Chronic Watery Diarrhea

Piroon Mootsikapun, M.D.

A 34-year-old man presented with low-graded fever, watery diarrhea and weight loss for a month. He had received treatment with 3-day oral ciprofloxacin for multiple courses but his diarrhea was still ongoing. After he was referred to a

university hospital, anti-HIV antibody was tested and the result was positive. The modified acid fast stain of his feces was done which revealed in Figure 1. The size of the organism was 8-10 micron in diameter.

What is your diagnosis and management?

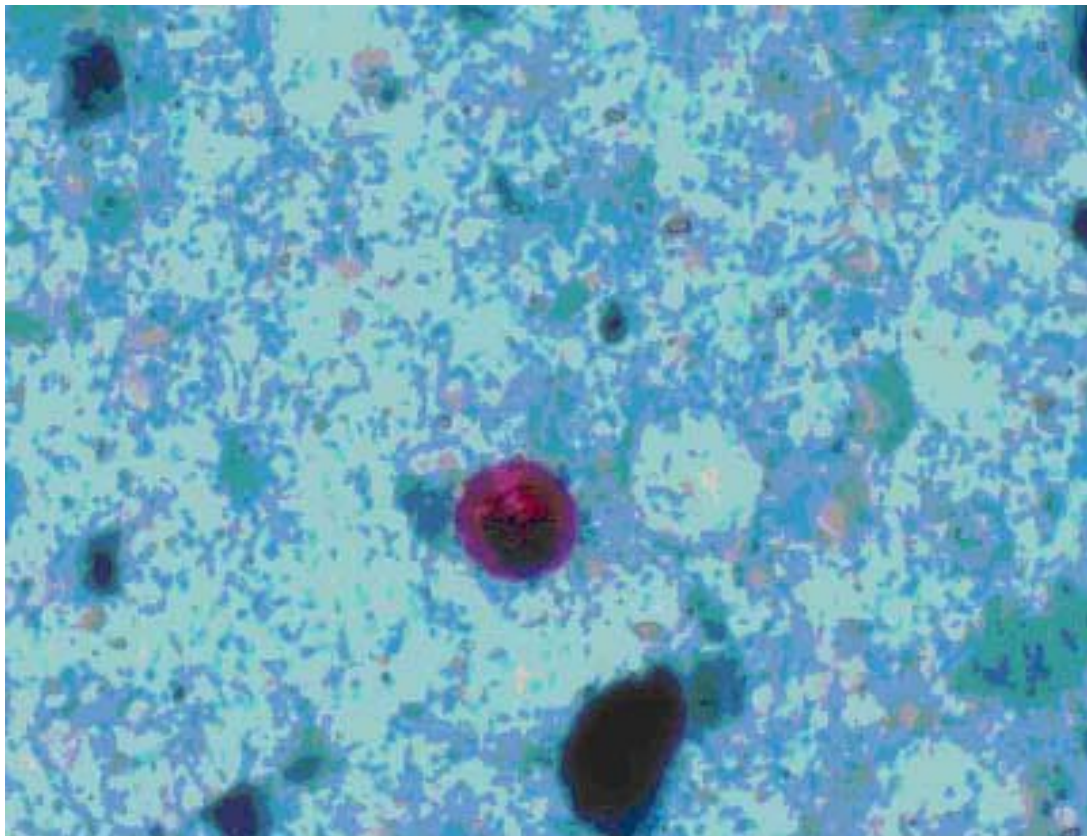


Figure 1.

(Please see the answer of this Photo Quiz on page 119)