

# COMMON CONSULTATION FROM OTHER DEPARTMENTS

**พ.อ.ธนະพันธ์ พิบูลย์บรรณกิจ**

อาจารย์พิเศษ หน่วยโรคติดเชื้อ กองอายุรกรรม รพ.พระมงกุฎเกล้า

**น.อ.ธนาสนธิ์ ธรรมกุล**

หน่วยโรคติดเชื้อ กองอายุรกรรม รพ.ภูมิพลอดุลยเดช

**รศ. นพ. ภิรุญ มุตสิกพันธุ์**

หน่วยโรคติดเชื้อ ภาควิชาอายุรศาสตร์ คณะแพทยศาสตร์ มหาวิทยาลัยขอนแก่น

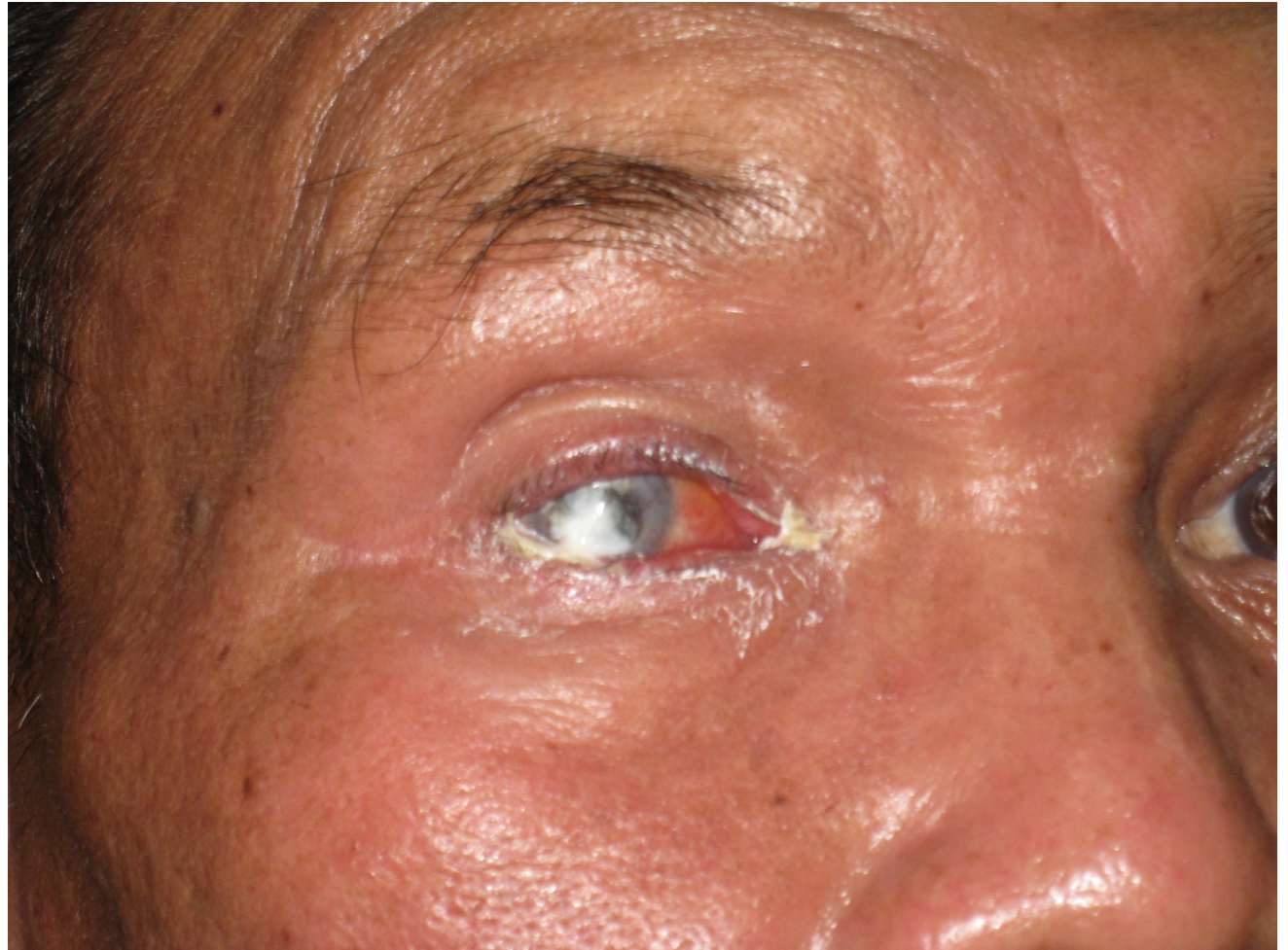
# Common consultation from other departments

OPHTHALMOLOGY (EYE)	Endophthalmitis, retinitis, uveitis, keratitis
OTOLARYNGOLOGY (ENT)	Fungal sinusitis, deep neck space infection, parotid abscess
OB/GYNS	Fever in CA cervix/CA ovary/CA endometrium
ORTHROPEDICS	Chronic osteomyelitis, Prosthetic joint infections, r/o TB spine
PMR	UTI
SURGERY	Fever in post op abdominal surgery/CA colon/CHCA/CNS SHUNT/GRAFT

- อายุ 54 ปี
- เบาหวาน 10 ปี
- ปวดตาขวา ตามัว มา 1 สัปดาห์
- มีไข้สูงเป็นพักๆ
- ไม่มีประวัติ trauma ที่ตา

**Diagnosis?**

**Endogenous  
endophthalmitis**



# Endophthalmitis

- infection inside the eye involving the vitreous and/or aqueous humors

Acute post-cataract	Coagulase-negative staphylococci (70% of cases), other Gram-positive cocci (25%)
Chronic post-cataract	<i>Propionibacterium acnes</i>
Post-injection	Coagulase-negative staphylococci, viridans streptococci
Bleb-related	Streptococci, <i>Haemophilus influenzae</i>
Post-traumatic	<i>Bacillus cereus</i> , coagulase-negative staphylococci (fungi in some cases)
Endogenous bacterial	<i>Staphylococcus aureus</i> , streptococci, Gram-negative bacilli (e.g. <i>Klebsiella</i> )

# Endogenous endophthalmitis

- bacteremic seeding of the eyes
- Endocarditis related 40%
- urinary tract infections
- indwelling central venous catheters
- illicit injection drug use
- procedures such as endoscopy
- In Taiwan, Singapore, and SEA, liver abscess caused by *Klebsiella pneumoniae* is the source of 60% of cases

# Endogenous endophthalmitis

- Blood cultures are positive in 75% of cases, as are vitreous cultures
- Treatment of the underlying source of bacteraemia with systemic antibiotics is necessary
- but this will not effectively treat the endophthalmitis: intravitreal antibiotics and, usually, a vitrectomy are necessary

# Endophthalmitis

- Srinagarind hospital, Khon Kaen 2012-2016

**Table 1** Types of endophthalmitis in 411 patients in the study

Types of endophthalmitis	No	Percentage
Post-traumatic	183	44.53
Post-operative	132	32.12
Endogenous	72	17.52
Keratitis-associated	16	3.89
Bleb-related	5	1.22
Post-intravitreal injection	3	0.72
Total	411	100.00

# Endophthalmitis

- Positive cultures were found in 172 (41.25%) of 417 eyes.
  - Bacteria were isolated in 157 eyes (91.28%), Gram positives in 20 eyes (76.43%) and Gram negatives in 37 eyes (23.57%)
  - fungi in eight eyes (4.65%)
  - mixed organisms in seven eyes (4.07%)
- 
- coagulase-negative *Staphylococcus* (36), *Bacillus* spp. (24), *Streptococcus pneumonia* (20),  $\beta$ -hemolytic streptococcus (12), *Pseudomonas* spp. (9), *Klebsiella* spp. (9), and *Enterococcus* spp. (8)
  - Post-traumatic - *Bacillus* spp.
  - Post-operative - coagulase-negative *Staphylococcus*.
  - Endogenous - Group B  $\beta$  hemolytic Streptococcus, *Klebsiella* spp., and *Escherichia coli*

# Endophthalmitis

- Srinagarind hospital, Khon Kaen 2012-2016

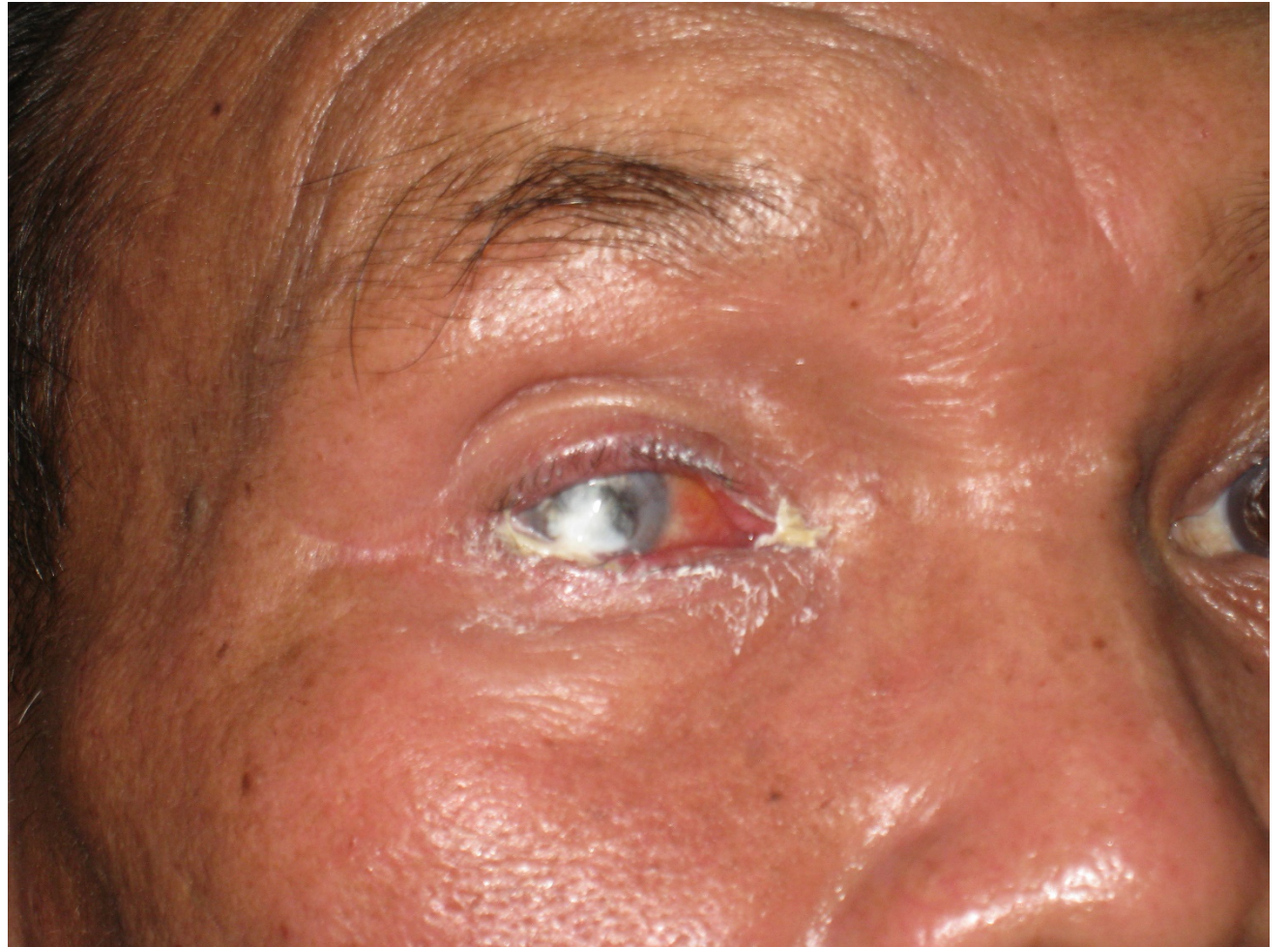
**Table 3** Treatment modalities of 417 eyes in the study

Treatment modalities	No	Percentage
Medical treatment	78	18.71
Pars plana vitrectomy	174	41.72
Par plana vitrectomy with silicone oil	87	20.86
Destructive surgery	78	18.71
Total	417	100.00

- Hemo culture
- *Klebsiella pneumoniae*

### Investigation?

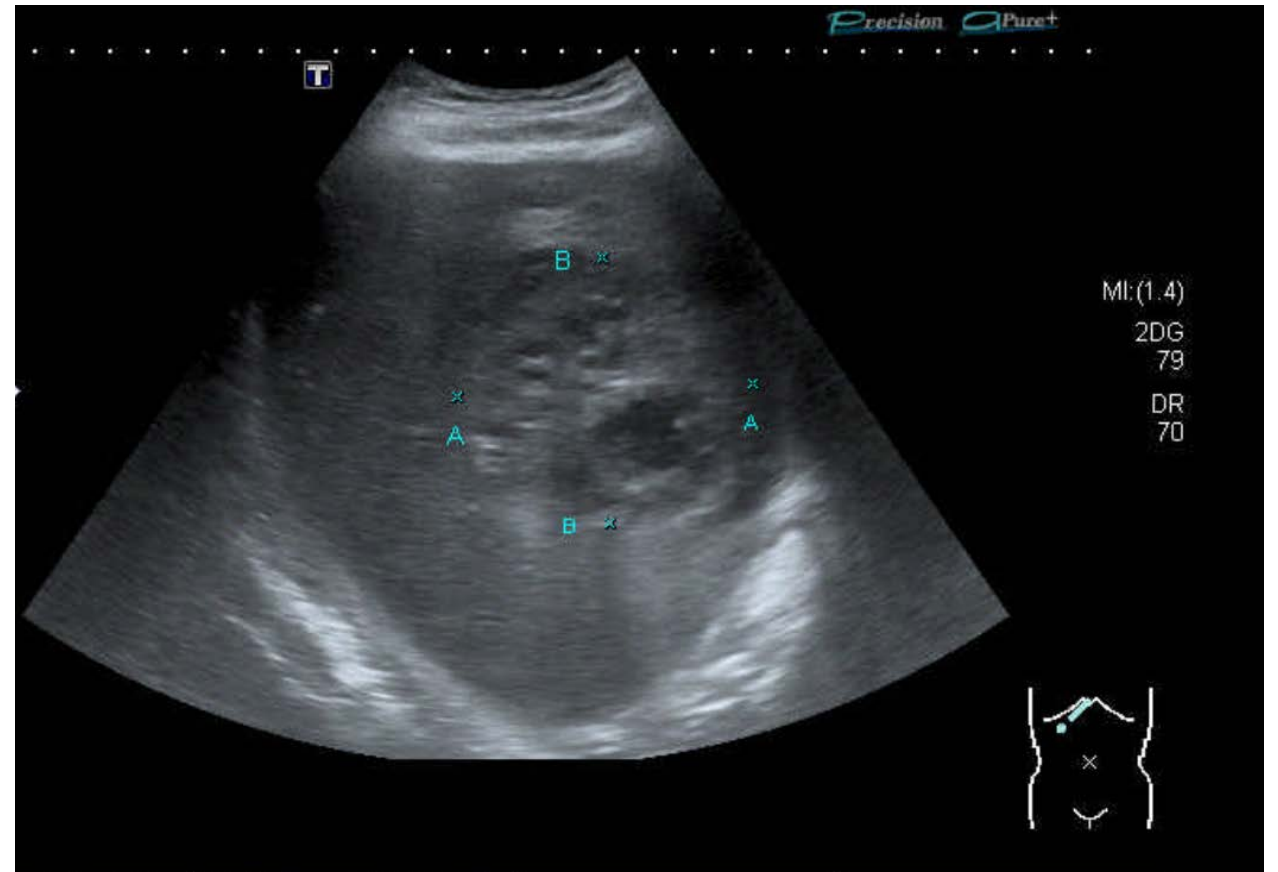
U/S abdomen  
CVS exam  
Echocardiogram



- Hemo culture
- *Klebsiella pneumoniae*

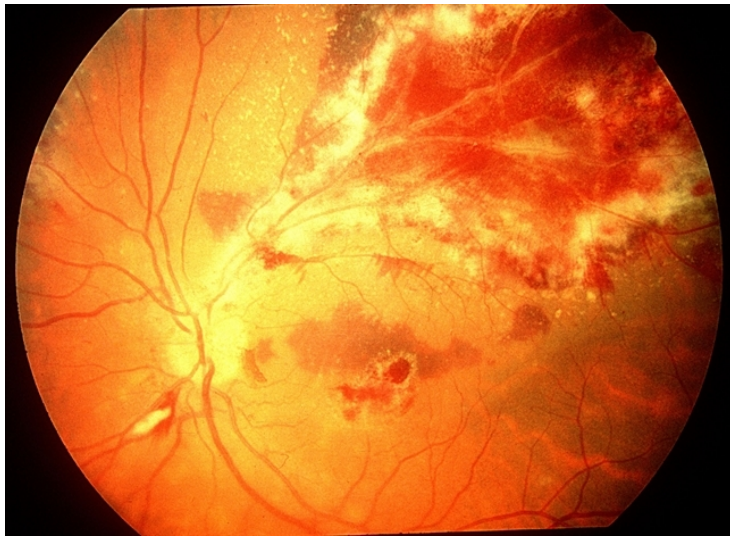
## Investigation?

U/S abdomen  
CVS exam  
Echocardiogram

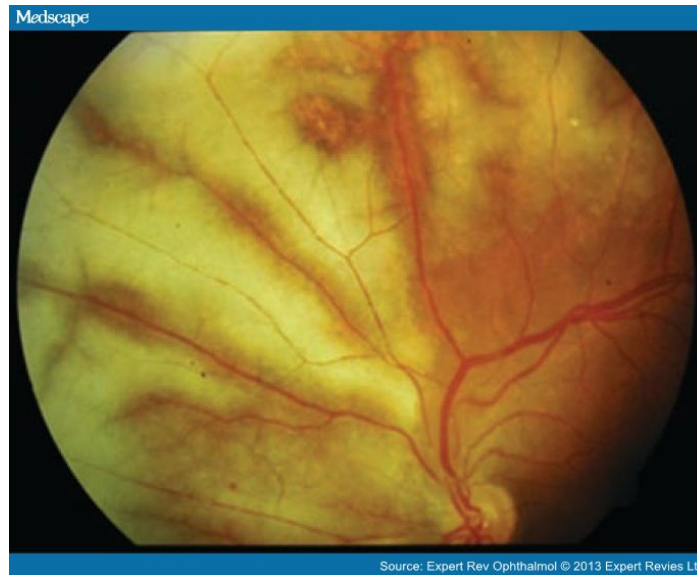

# RETINAL PROBLEMS

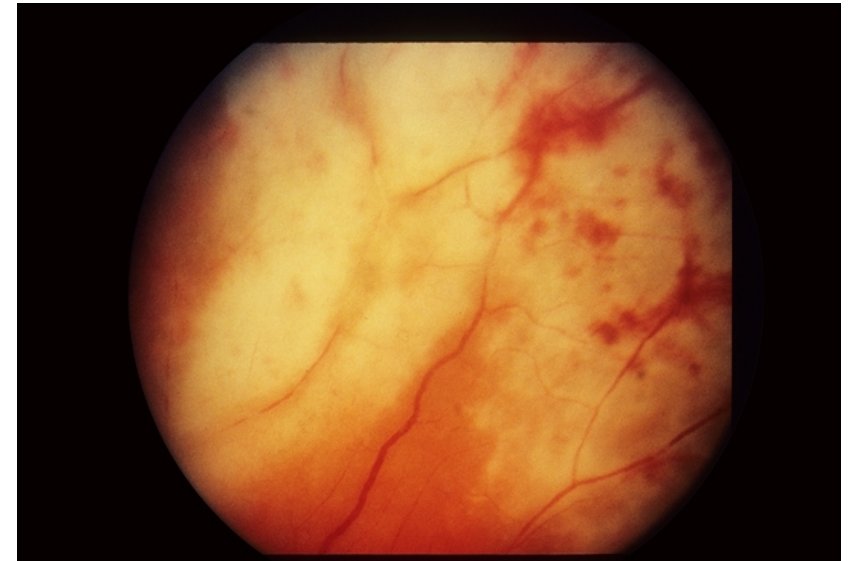
- CMV retinitis
- Posterior outer retinal necrosis (PORN)
- Acute retinal necrosis (ARN)



CMV retinitis



PORN



ARN

# RETINAL PROBLEMS

- CMV retinitis
  - Ganciclovir 5 mg/kg q 12 hr + intravitreal ganciclovir x 14d + ART -> maintenance intravitreal GCV 2-3/WK until CD4 > 50/mm<sup>3</sup>
- Posterior outer retinal necrosis (PORN)
- Acute retinal necrosis (ARN)
  - HZV most common cause
  - Acyclovir 10 mg/kg iv q 8 hr -> oral form  $\geq$  14 d

# KERATITIS

- Fungal keratitis
- *Fusarium*
- Surgery + Voriconazole topical
- *Pythium*
- Surgery